

Haemorrhage in muscles of the neck and back region in a case of drowning

Semih Petekkaya¹, Mustafa Dogan², Nusret Ayaz³, Osman Celbis³

¹Justice Ministry, Council of Forensic Medicine, Malatya Group Chairmanship, Malatya, Turkey.

²Justice Ministry, Council of Forensic Medicine, Iğdır Branch, Iğdır, Turkey.

³Inonu University Medical School, Department of Forensic Medicine, Malatya, Turkey.

Address for correspondence:

Nusret Ayaz,
Inonu University Medical School,
Department of Forensic Medicine,
Malatya, Turkey.
nusretayaz@gmail.com

Received: March 08, 2016

Accepted: April 02, 2016

Published: April 12, 2016

ABSTRACT

In corpses removed from water, when there are no specific findings related to drowning in water, there are difficulties in determining the mechanism and origin of death. The death of the individual may be related to natural causes before entering the water or when in the water, or to trauma or other non-natural causes. A 40-year old woman who had been married for approximately 3 years was reported missing for 1 day. She had argued with her husband 3 days previously about children from a previous marriage. She had threatened to drown herself. Eyewitnesses stated that she had previously been rescued after a suicide attempt in the same pond where her body was found. Three days after the attempted suicide, while her husband was away from the city, the woman went out without telling the family. As she had previously stated to her brother that she would commit suicide by water, the family searched the pond and found the body floating face-down in the water. In the case here presented, the rarely seen finding of intramuscular haemorrhage was observed. It is emphasized that attention must be paid to these rare findings when differentiating between strangulation and drowning.

KEY WORDS: Drowning; Haemorrhage; Death; Autopsy

INTRODUCTION

In corpses removed from water, when there are no specific findings related to drowning in water, there are difficulties in determining the mechanism and origin of death [1-4]. The death of the individual may be related to natural causes before entering the water or when in the water, or to trauma or other non-natural causes [5]. In the external examination of bodies related to time in water, it has been reported that there may be a wrinkled 'washerwoman' appearance to the skin of the hands and feet, foam around the mouth and nose, postmortem staining, and material contained in the water on the body [1, 2]. When conditions emerge associated with other causes of death, in bodies which have remained in the water for a sufficient time, indicators are formed associated with the time in the water [1]. Therefore in cases of drowning in water, diagnosis should be made by an evaluation of autopsy findings together with histopathology and toxicology examination reports, findings of the scene examination and witness statements.

The findings of internal bleeding which form in the muscles of the neck region in assault cases of strangulation by hand or rope, are rare in cases of drowning. In the case here presented.

CASE REPORT

A 40-year old woman who had been married for approximately 3 years was reported missing for 1 day in August. She had argued with her husband 3 days previously about children

from a previous marriage. She had threatened to drown herself and stated that her husband would be responsible. Eyewitnesses stated that she had previously been rescued after a suicide attempt in the same pond where her body was found. The witness stated that the woman had suddenly jumped into the water and was thrashing about, so he had jumped into the water himself and rescued her. In the examination made on the same day in the hospital, no traumatic lesions were observed on her body. No psychiatric follow-up or treatment was applied at the hospital. She made no complaints about any person as the reason for the suicide attempt.

Three days after the attempted suicide, while her husband was away from the city, the woman went out without telling the family. She was reported missing to the authorities by the family. As she had previously stated to her brother that she would commit suicide by water, the family searched the pond and found the body floating face-down in the water. Death was determined in the evaluation by the healthcare team. No resuscitation intervention was made. In the examination made by the scene-of-crime investigation team, no findings were determined which would suggest murder or accident, so it was considered to be suicide. When her clothes were examined, no tears were found. The deceased had been followed up in the psychiatric clinic for 5 years for a diagnosis of depressive episodes and anxiety disorder. Medical treatment appropriate to this diagnosis had been administered. At the time of death, the family reported that

there was no active medication or narcotic or stimulant substance. No diagnosis of any significant physical disease was found in the medical history. The family of the deceased complained about the husband in relation to the incident, stating that he had exerted pressure to commit suicide. The husband returned to the city when notified of the incident. However, fearing family reprisals, he did not attend the funeral.

AUTOPSY FINDINGS

In the external examination, foam cone was observed in the nose and mouth [Figure 1]. No abrasions and/or contusions were observed on the body in the anterior and posterior neck region [Figure 2]. No findings of decay were determined on the body. There were findings of maceration on the hands and feet [Figure 3]. Pondweed and mud-washing was seen on the body. In the internal examination, blood was in the mastoid air cells bilaterally. The lungs covered the upper part of the heart. Serous fluid of 150 ml was drained from the right and left chest cavity. There was the same amount of white-coloured foamy fluid in the trachea and bronchi [Figure 4]. The right lung was weighed as 743 g and the left lung as 632 g. There was an advanced degree of oedema in both lungs [Figure 5]. In the slices there was seen to be foamy fluid outlet. There was no any fractured cervical or thoracic spine. There was no any fractured cervical or thoracic spine. In the stomach, there was 400 ml of dirty-white coloured fluid of a runny consistency. Findings of congestion were determined in the other organs. In the left and right sternocleidomastoid muscles, areas of intramuscular haemorrhage were observed bilaterally [Figure 6]. In both paravertebral muscle groups and in the right sternohyoid muscle, an area of intramuscular haemorrhage was observed [Figure 7]. In the dissection of the back, areas of intramuscular haemorrhage were seen bilaterally in the muscle groups over the scapula [Figure 8].

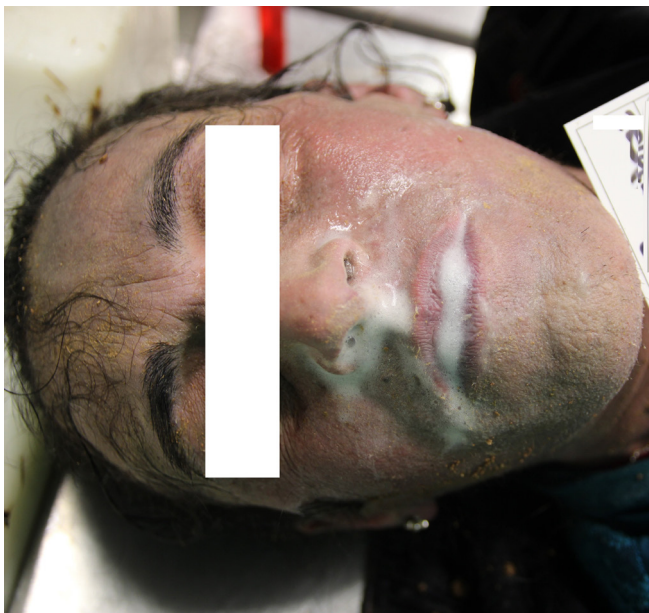

Figure 1. Foam cone in the nose and mouth.

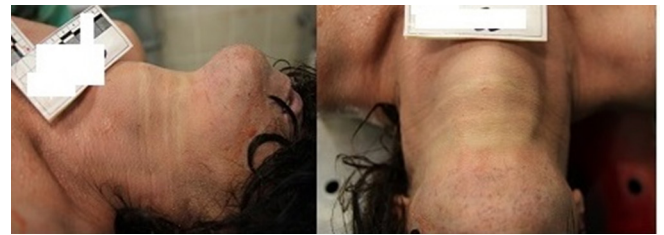

Figure 2. No abrasions and/or contusions in the anterior and posterior neck region.

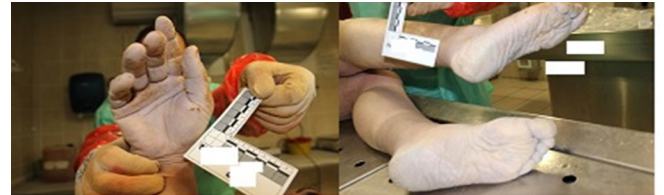

Figure 3. Maceration on the hands and feet.

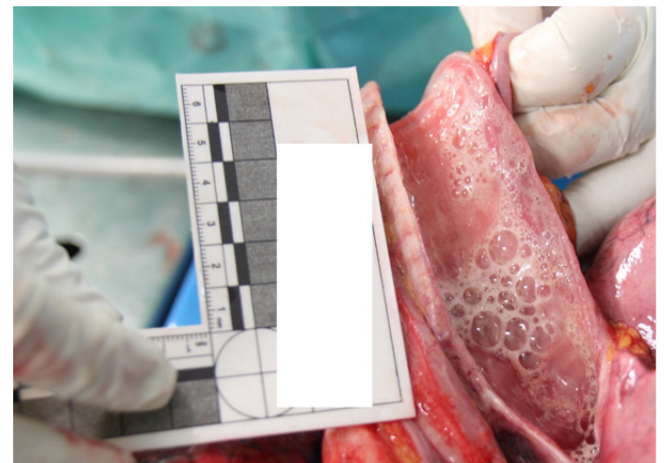


Figure 4. White-coloured foamy fluid in the trachea and bronchi

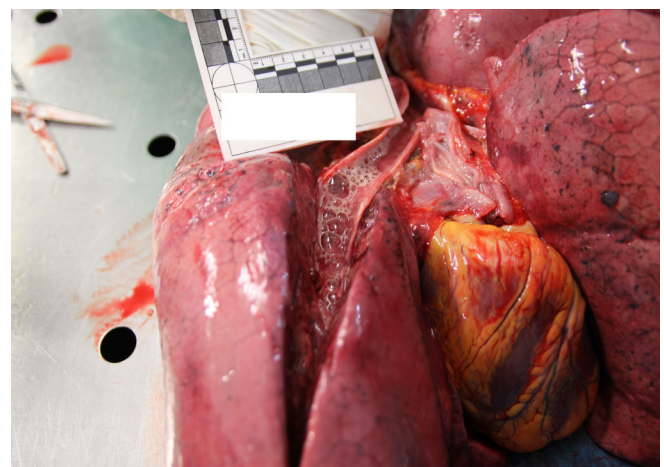


Figure 5. oedema in both lungs.

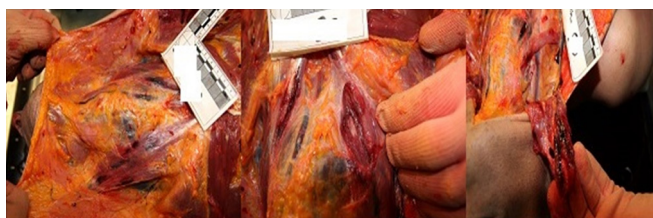

Figure 6. Haemorrhage in the left and right sternocleidomastoid muscles.

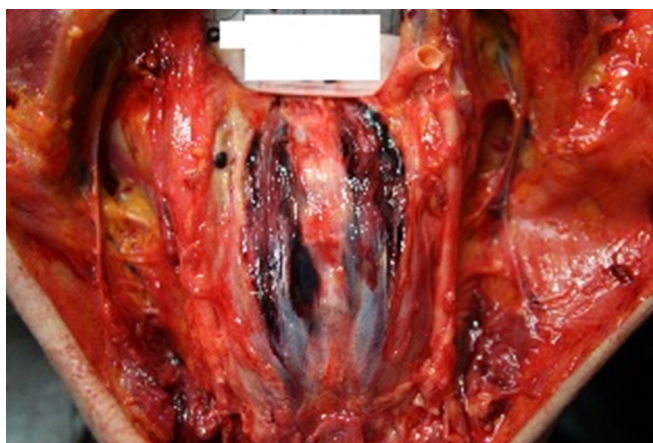

Figure 7. Haemorrhage in both paravertebral muscle groups and in the right sternohyoid muscle, an area of intramuscular.

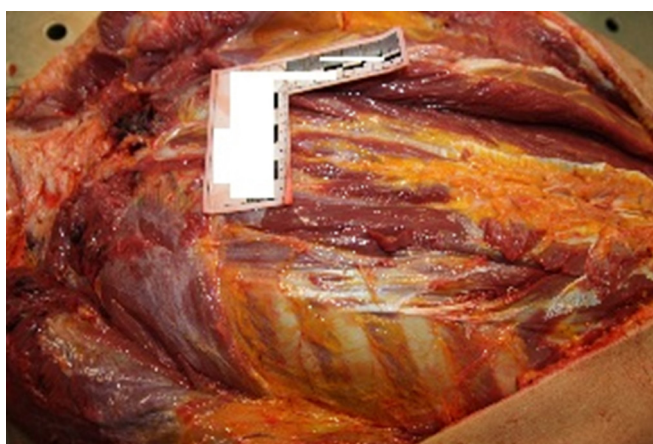

Figure 8. Intramuscular haemorrhage bilaterally in the muscle groups over the scapula.

For histopathological evaluation, separate samples were taken from the heart, brain, kidney, liver, lungs, pancreas and muscle groups and sent to the pathology laboratory in 10% formaldehyde. Following routine tissue preparation of the samples taken from the tissues, staining with haematoxylin-eosin (H-E) was applied and evaluation was made under a light microscope. In the microscopic examination, there were emphysematous changes in the lungs, intra-alveolar erythrocytes in a focal area, inflammation stasis, and focal oedema. There was perivascular and interstitial fibrosis of a mild severity in the heart and atheroma plaque at the rate of 15%-20% in the coronary arteries. In the separate evaluation

of the muscle groups, extensive areas of fresh haemorrhage were seen.

For the systematic toxicology evaluation, samples were taken of the liver, kidneys, stomach contents, vitreous, bile fluid and blood and were sent to the chemistry laboratory. In the examination of the samples using a Gas Chromatography Mass Spectrometer (GC/MS), no alcohol, sedative, narcotic or stimulant substance was found and in the systematic examination, no toxicological substance was found.

When the findings of the scene-of-crime investigation, witness statements, autopsy findings, histopathology and toxicology examination reports were evaluated together, it was concluded that the deceased had died by drowning through suicide.

DISCUSSION AND CONCLUSION

When there are no eyewitnesses or camera records of the incident, determining the origin of death of bodies found in water, is difficult [6-8]. Just as a body may be thrown into water to disguise a murder, so an individual may also drown without witnesses [4]. As the autopsy findings of drowning are non-specific, great care must be taken in the determination of the diagnosis of drowning and the origin [1].

Intramuscular haemorrhage seen in the neck and back region in autopsies is important in respect of clarifying the origin of death as it may result from blunt trauma [8]. These types of lesions are easily formed by force applied to the neck region by hand or rope during strangulation or in the back region as a result of kicking and punching. It has been reported that haemorrhage is rarely seen in the pectoral, sternocleidomastoid, respiratory and auxiliary respiratory muscle groups in cases of drowning [3, 4]. In the current case, it is thought that for reasons such as vomiting, coughing, agitation and difficult respiration while drowning, the central venous pressure increased causing congestion in the neck anterior and posterior surface muscle groups and subsequent tearing of the blood vessels caused the haemorrhage. It can also be assumed that after aspiration of water, agonal convulsion or hypercontraction which may be seen in the muscles, could also have caused bleeding.

In the external examination, no findings were determined of haematoma, abrasion or contusion on the skin. In the muscle groups showing findings of haemorrhage, no findings were observed of trauma in the fascia around the muscle or in the subcutaneous soft tissue. There was no history of trauma when removing the body from the water or during transport and there was no history of medical intervention. Therefore, together with evaluation of the scene-of-crime examination and witness statements, it was considered that the intramuscular haemorrhage had not developed due to trauma, but had occurred while drowning.

During resuscitation attempts on bodies removed from water, traumatic lesions may be created on the skin, in fat tissue and muscle groups [7-9]. Therefore, the resuscitation

history must be questioned when haemorrhage is determined in the muscles of corpses. In the current case, no resuscitation was made as death was determined in the evaluation made by the healthcare personnel.

Due to hypothermia when the water temperature is low, haemorrhage may be seen because of increased muscle activity. In these types of cases, haemorrhage may occur through ruptures in the cavernous structures of the respiratory and auxiliary respiratory muscles in a state of panic and excessive tension [3]. If possible, the water temperature should be measured and recorded. In the current case, as it was summer, the water temperature would have been 25°C -29°C. No autopsy findings associated with hypothermia were observed.

Existing diseases in the individual especially bleeding disorders may cause intramuscular haemorrhage. Therefore, medications used and medical history are important in respect of the determination of the cause of death.

In a retrospective study by Carter et al in which 99 cases of drowning were examined, haemorrhage in the neck region was found in 8 (8.1%) cases [5]. Püschel et al made a prospective examination of 39 cases of drowning and determined intramuscular haemorrhage in the neck, trunk and upper extremity muscles in 20 cases [3,10]. In both studies, it was reported that spasms of the neck region muscles were caused by agonal convulsion and hypercontraction while drowning [3-5]. The high rate seen in the study by Püschel et al can be attributed to a more detailed histopathological examination. According to Carter et al during decomposition it can cause misinterpretations hypostasis and haemorrhage on neck muscles. In our case decomposition had not been developed yet and in histopathological evaluation there was fresh haemorrhage on neck and posterior muscles.

In bodies removed from water with haemorrhage in the neck and back region muscle groups, the cause of death should not be immediately interpreted as the result of assault such as strangulation by hand or rope. These findings of haemorrhage can be seen in cases of drowning as a result of torn blood vessels following congestion in the neck anterior and posterior surface muscles with an increase in central venous pressure. Investigation must be made in respect of trauma with findings of haematoma, abrasions or contusions on the skin and findings of haemorrhage in the fascia around the muscle in muscle groups and in the subcutaneous fat tissue.

REFERENCES

1. De la Grandmaison GL. Is there progress in the autopsy diagnosis of sudden unexpected death in adults? *Forensic Sci Int.* 2006;156(2-3):138-44.
2. Piette MH, De Letter EA. Drowning: Still a difficult autopsy diagnosis. *Forensic Sci Int.* 2006;163(1-2):1-9.
3. Püschel K, Schulz F, Darrmann I, Tsokos M. Macromorphology and histology of intramuscular hemorrhages in cases of drowning. *Int J Legal Med.* 1999;112(2):101-6.
4. Alexander RT, Jentzen JM. Neck and scleral hemorrhage in drowning. *J Forensic Sci.* 2011;56(2):522-5.
5. Carter N, Ali F, Green MA. Problems in the interpretation of hemorrhage into neck musculature in cases of drowning. *Am J Forensic Med Pathol.* 1998;19(3):223-5.
6. Schulz F, Buschmann C, Braun C, Püschel K, Brinkmann B, Tsokos M. Haemorrhages into the back and auxiliary breathing muscles after death by hanging. *Int J Legal Med.* 2011;125(6):863-71.
7. Akhlaghi M, Okazi A, Ghorbani M, Taghaddosi-Nejad F, Mazinani R, Mehdizadeh F, et al. Causes of death accompanying by soft tissue neck hemorrhage. *Int J Med Tox For.* 2013;3(1):10-9.
8. Schulz F, Lach H, Püschel K. Nontraumatic intramuscular hemorrhages associated with death caused by internal diseases. In: Tsokos M, editor. *Forensic Pathology Reviews.* New York: Humana Press; 2011. p.129-35.
9. Henssge C, Wang H, Hoppe B. Light microscopical investigations on structural changes of skeletal muscle as artifacts after postmortem stimulation. *Forensic Sci Int.* 2002;125(2-3):163-71.
10. *Forensic Pathology Review.* Eds.: M Tsokos In: Lunetta P, Modell JH. *Macroscopical, microscopical and laboratory findings in drowning victims.* Vol 3. Humana Press Inc. Totowa.2005. p. 3-77.

© SAGEYA. This is an open access article licensed under the terms of the Creative Commons Attribution Non-Commercial License (<http://creativecommons.org/licenses/by-nc/3.0/>) which permits unrestricted, noncommercial use, distribution and reproduction in any medium, provided the work is properly cited.

Source of Support: Nil, Conflict of Interest: None declared